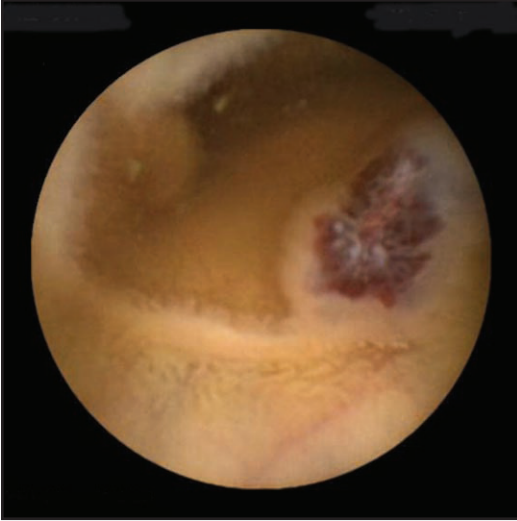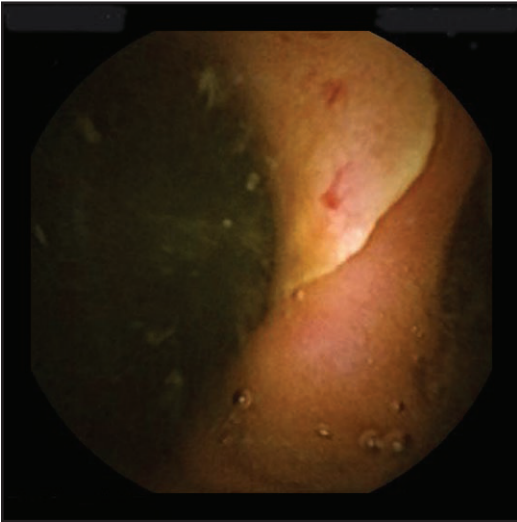
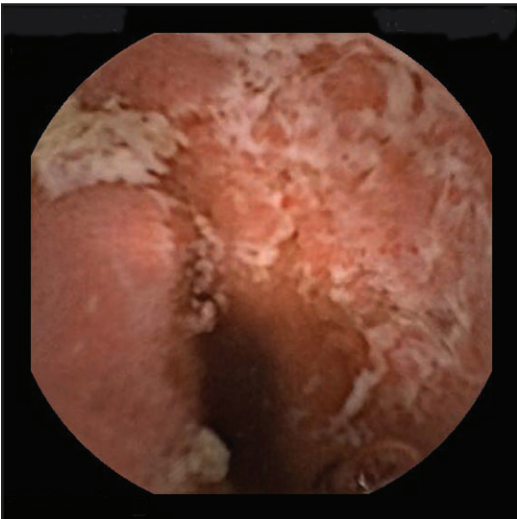


**Figure 48-1.** Blue rubber bleb nevus syndrome in a 4-year-old patient.



**Figure 48-2.** Meckel diverticulum and ulcer in a 14-year-old patient.



**Figure 48-3.** Crohn's disease in an 18-year-old patient.